

COMPLETE SPONTANEOUS BONE REGENERATION FOLLOWING PARTIAL MANDIBULECTOMY

A. E. ABDULAI

Department of Oral and Maxillofacial Surgery, University of Ghana Dental School, Korle Bu Teaching Hospital. P. O. Box 77, Accra, Ghana.

Corresponding Author: Dr. A. E. Abdulai

E-mail address: aemilabdulai@yahoo.com

Conflict of Interest: None declared

SUMMARY

Bone formation in small deposits following the loss of part of the mandible has often been reported in the literature, but reports of complete bone regeneration extending over the entire anterior mandible from angle to angle is rare. Even rarer, are reports on the behaviour of such new bone in terms of facial development, over a long term and the effect of load carrying on it. Presented here is an unusual case of bone regeneration after resection of a large portion of the mandible in a 12 year-old female patient with ameloblastoma in the anterior mandible. Inter-maxillary fixation, bone grafting, or insertion of any kind of implant was not employed. Spontaneous bone regeneration was noted six weeks after surgery, and the entire resected portion of the mandible completely regenerated when the patient was seen again six years later. Mandibular growth was not significantly affected and thirteen years after her treatment, including five years of partial denture usage over the new bone, the shape of the mandible is satisfactory without any evidence of bone resorption. The periosteum was totally preserved, perhaps accounting for the complete bone regeneration and normal mandibular growth and form.

Key Words: Mandibulectomy; Complete; Spontaneous; Bone; Regeneration.

INTRODUCTION

Spontaneous bone regeneration following the loss of part or the entire mandible has occasionally been reported in the literature. The causes of reported extensive bone loss include shot gun blast injury^{1,2}, enucleation of large cysts^{3,4} and infection.⁵⁻⁷ By far however, the commonest reported cause of extensive bone loss has been as a result of partial mandibulectomy⁶⁻¹⁰ for the treatment of a tumour or tumour-like condition. A search on the World Wide Web reveals only a total of twenty cases of spontaneous mandibular bone regeneration reported in the English literature by the end of the 2007. Only three of these cases were adults above 32 years. The rest were child patients with ages ranging from 8 to 15 years. In most of the reported cases, some kind of stabilization in the form of a maxillo-

mandibular fixation (MMF)^{7,9}, Kirschner wire¹ or titanium mesh⁸ was employed in the surgery. Several explanations for this remarkable phenomenon have been proposed and include the development of new bone from intact periosteum³⁻¹⁰ or its fragments^{1,10} which serve as the direct source of osteogenic cells, and from regenerated juvenile periosteum.²

Presented in this report, is yet another case of spontaneous bone regeneration of the mandible after partial mandibulectomy in a 12 -year-old female patient for the treatment of ameloblastoma. Long term follow-up of regenerated mandible is rare in the literature. The purpose of this report is to highlight the course and behaviour of the regenerated bone over a period of thirteen years, including five years of partial denture usage over the new bone. Though the periosteum was carefully preserved as in many others reported, in this case no bone graft or implant was used, and no form of stabilization was employed during the healing period.

CASE REPORT

Clinical Examination

A 12-year old girl child (M.A.) was referred for evaluation of her jaw swelling that had been noticed, and had grown slowly over a year. General examination revealed an otherwise healthy child with her haemogram and blood chemistry within normal range. Aspiration of the lesion produced a slimy sero-sanguineous fluid, and a posterior-anterior view of radiograph of the jaws (Figure1) showed a cloudy expansion of the mandible from the angle region on the right to the premolar region on the left, with the lower right mandibular canine inferiorly displaced. A clinical diagnosis, later confirmed histologically, as ameloblastoma was made. Immediate pre-operative findings revealed an extensive tumour involving the entire anterior mandible, necessitating total resection despite her age.

Surgical Procedure

Under general anaesthesia, an extra-oral surgical approach via a sub-mandibular incision was performed. The tumour was exposed by blunt dissection and the periosteum neatly cut along the lower mandibular bor-

der in the direction of the surgical incision and carefully stripped off on both sides of the mandible, thus entirely exposing the tumour, which was then completely resected. The periosteum was carefully sutured back in place and the wound closed in layers without inserting any drain, graft or implant. She was placed on one mega-unit crystalline penicillin six hourly, I.V/I.M for a week.

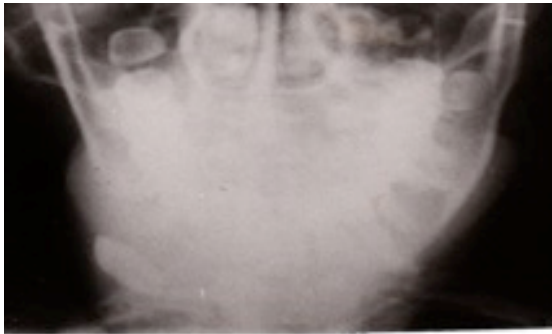


Figure 1. Radiograph showing posterior-anterior view of the jaws. Note the displaced right mandibular canine and the extent of the lesion at presentation.

Postoperative Course

This was uneventful, and the patient was discharged home after 10 days. Interestingly, when she was reviewed six weeks post op, bone regeneration was noted following a bimanual palpation of some firm callus-like tissue replacing the resected mandible. This was remarked in her notes and she was scheduled for further review and post op x-ray, but then she failed to keep the appointment and got lost to follow-up.

At 18, six years after her operation, she reappeared to request for a partial denture to replace her missing teeth. The mandible, at that time, appeared completely regenerated following a review of a radiograph, (Figure 2), taken to assess her for the construction of the partial denture (Figure 3).

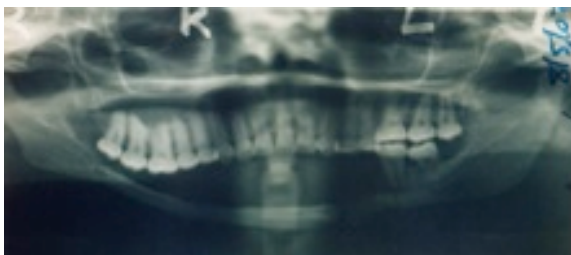

Figure 2 Orthopantomograph of the mandible taken six years post operative. Note the completely regenerated bone.

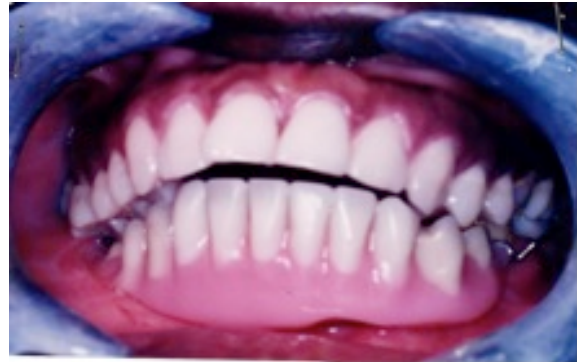

Figure 3 Photograph of patient showing close-up view of partial denture fitted in place

It was evident then that the patient's facial development was consistent with her age. Thirteen years after her treatment despite the weight carried on the regenerated bone, from the use of the denture, there is no evidence of bone resorption, and the shape of the mandible is satisfactory with no evidence of recurrence. (Figure 4)

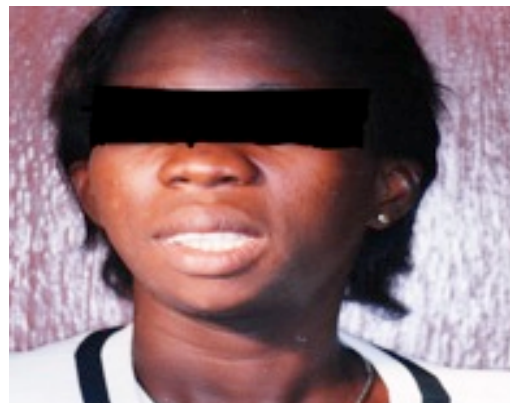

Figure 4 Photograph of the patient, (M.A.) 13 years post-op showing a partial denture fitted in place. Note the satisfactory development and shape of the mandible.

DISCUSSION

Spontaneous bone regeneration, an unexpected phenomenon that may take place following the loss of part or the entire mandible, has occasionally been reported in the literature. The reported causes of such extensive bone loss have included shot gun blast injury^{1,2}, enucleation of large cysts^{3,4} and infection.⁵⁻⁷ The commonest reported cause of extensive bone loss however, has been as a result of partial⁶⁻¹⁰ mandibulectomy for the treatment of a tumour or tumour-like condition.

Glenda H. de Villa *et al*⁸ presented, including their own, a total of 19 reports of spontaneous bone regeneration of the mandible in the English literature up to the

year 2002. In all of those reports, authors reported resecting a large portion of the mandible or repairing the remaining mandibular segments after an injury without expecting any bone regeneration to take place in such a large gap. New bone was discovered only during routine postoperative clinical and radiographic examinations. Nagase⁹ et al, noted eggshell radiopacity in the area of a resected condyle in an orthopantomogram taken 2 weeks postoperatively, Whiles Budal⁵ reported new bone formation between remaining mandibular stumps 2 weeks after resection of a large osteofibroma. A review of the literature presents several factors that may influence this process, and several suggestions by various authors have been put forward in an attempt to explain this phenomenon.

For instance both Adekeye⁶ and Nwoku⁷ suggested in their reports that preservation of periosteum, coupled with the young ages of their patients, possible genetic factors and infection may play important roles in rapid bone regeneration. Pramono,¹⁰ more recently, reported yet another case of spontaneous bone regeneration, and went on to suggest that unexpected spontaneous bone regeneration may be explained by the fact that periosteum, as the source of osteogenic cells, might be responsible for this process. Other factors mentioned in the literature include the presence of bony fragments,^{1,2} and of a temporary reconstruction material such as titanium mesh^{8,9} or Kirschner wire.^{1,2}

The patient reported here was treated for Ameloblastoma of the mandible, for which various surgical methods, both conservative and radical, could be used. The treatment method chosen in this case was influenced by factors such as the nature of presentation of the tumour, including the large extent and degree of bone involvement with tumour, the age of the patient and the limited resources including the lack of any form of reconstruction material and or the means to acquire it at the time. Six weeks after her surgery, bone regeneration was noted in the firm callus-like tissue replacing the resected mandible.

The young age of the patient, coupled with the preservation of the periosteum as already suggested by some previous reports^{6,7,10}, are some of the factors that could have contributed to this phenomenon. Unlike in most of the reports however, no significant infection^{6,7} was encountered here, and no form of maxillomandibular fixation (MMF)^{7,9}, Kirschner wire¹, or titanium mesh⁸ was employed in the surgery.

Kisner¹ reported that the regenerated mandible in his patient had attempted to replace the missing segment not only in substance but in position as well.

This was found to be the case in the patient reported here. Her entire anterior mandibular segment was replaced with new bone that was well formed and positioned.

Long-term follow-up of regenerated mandible is rare in the literature. The longest before now was a 5-year follow-up of a regenerated mandible presented by Budal.⁵ It showed bone regeneration from the right third molar to the left second molar. A situation quite akin to that reported here.

As seen in Figure 2, there was no interruption in the connection between the old and the new bone. A similar observation was made in a recent report,¹⁰ where although there was no external sign of disfigurement, the new mandible was apparently deformed in the area where the ramus had been pulled upward before the formation of new bone. Such observation according the authors, demonstrates that the newly regenerated bone behaved in a manner similar to that of the original bone, and lead them to conclude in their report that an explanation for this unexpected bone regeneration may be derived from the mechanism of fracture healing. The difference according to them is that the former process takes place in a large mandibular defect, whereas the latter occurs when the bony segments are placed in close contact with each other and fixed.

In conclusion, the uninterrupted connection between the old and new bone and the lack of vertical height loss in the new bone, despite the use of a denture over it for over five years in the case reported here, lays further credence to the fact that the newly regenerated bone behaves in a manner similar to that of the original bone, and that its regeneration may be derived from the mechanism of fracture healing, with intact periosteum being essentially necessary.

REFERENCES

1. Kisner WH. Spontaneous posttraumatic mandibular regeneration. *Plast Reconstr Surg* 1980; 66:442-7.
2. Shuker S. Spontaneous regeneration of the mandible in a child. A sequel to partial avulsion as a result of a war injury. *J Maxillofac* 1985 Apr; 13(2):70-3.
3. Chiapasco M, Rossi A, Motta JJ, Crescentini M. Spontaneous bone regeneration after enucleation of large mandibular cysts: a radiographic computed analysis of 27 consecutive cases. *J Oral Maxillofac Surg*. 2000 Sep;58(9):942-8
4. Di Dio M, De Luca M, Cammarata L, Pierazzi G. Bone regeneration after removal of a mandibular cyst and following prosthetic rehabilitation with

- implants. Case report. *Minerva Stomatol.* 2005 Jun; 54(6):373-8.
5. Budal J. The osteogenic capacity of periosteum. *Oral Surg* 1979; 47:227-9.
 6. Adekeye EO. Rapid bone regeneration subsequent to subtotal mandibulectomy. *Oral Surg* 1977; 44:521-6.
 7. Nwoku AL. Unusually rapid bone regeneration following mandibular resection. *J Maxillofac Surg* 1980; 8:309-15.
 8. Glenda H. de Villa, et al Spontaneous bone regeneration of the Mandible in an Elderly Patient: A Case Report and Review of the Literature. *Chang Gung Med J* 2003; 26:363-9.
 9. Nagase M, Ueda K, Suzuki I, Nakajima T. Spontaneous regeneration of the condyle following hemimandibulectomy by disarticulation. *J Oral Maxillofac Surg* 1985; 43:218-220.
 10. Pramono D Coen. Spontaneous bone regeneration after mandible resection in a case of ameloblastoma: A case report. *Annals of the Academy of Medicine, Singapore.* 2004, Jul; 33(4 Suppl):59-62.
-